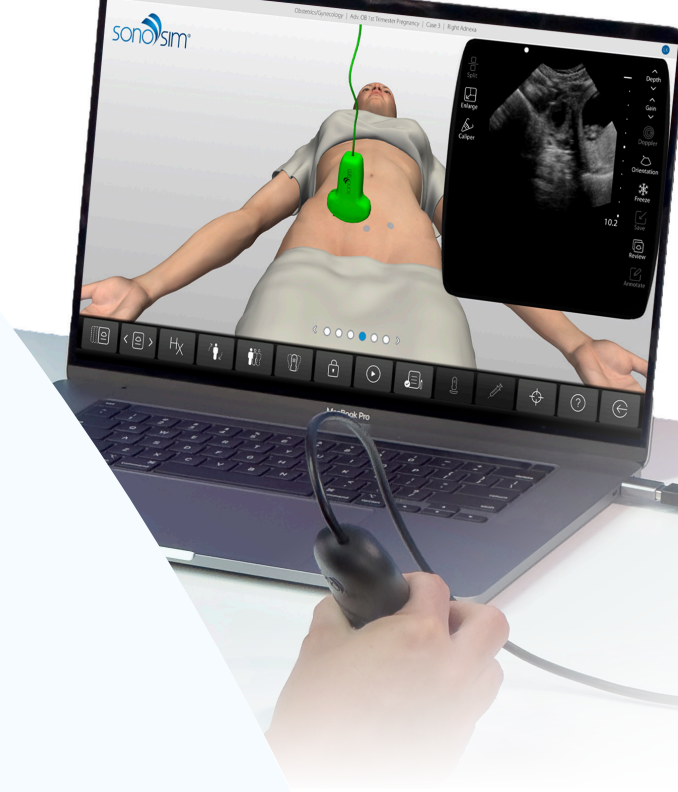
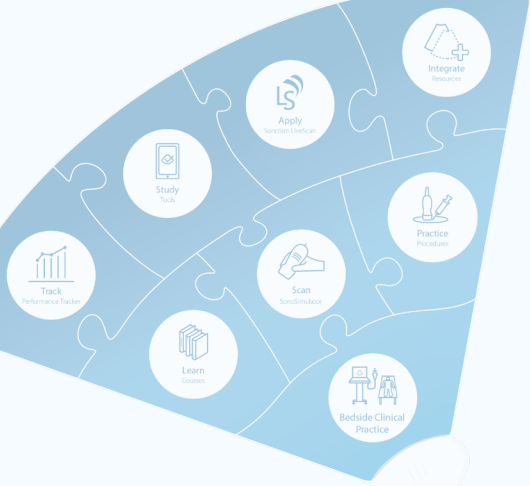


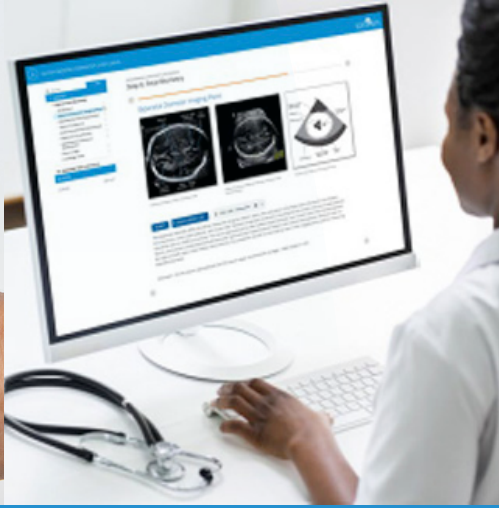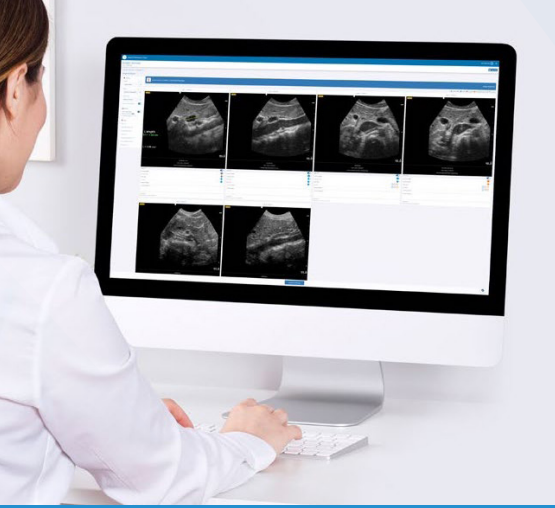# Family Medicine

## Comprehensive POCUS Education Ecosystem

POCUS has become vital but can be very challenging & costly to integrate using only traditional approaches.

**SonoSim helps busy family medicine residencies with:**

- Standardization of programming & tracking of resident progress
- Curriculum building, additional expertise, & efficiency
- Pathologic scanning cases & learner feedback tools



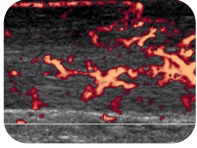
The Easiest Way to Learn & Teach Ultrasonography®



Explore Our Proven Approach for Family Medicine

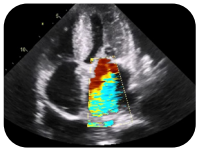
# Streamline Training with a Turn-Key Platform

## Fully Mapped to AAFP Guidelines\*



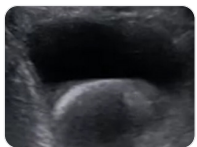
MSK

- Cellulitis versus abscess
- Foreign body
- Joint effusions/bursitis & fractures
- Tendon rupture/tear & tendonitis/tendinopathy
- Risks, benefits, indications, and contraindications to ultrasound-guided injection and aspiration
- Shoulder: Rotator cuff integrity
- Knee: Medial collateral ligament, lateral collateral ligament, and patellar tendon integrity
- Ankle: Anterior talofibular ligament, calcaneofibular ligament, & posterior talofibular ligament integrity
- Median nerve area & carpal tunnel
- And more...



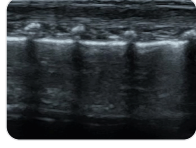
Cardiac

- Pericardial effusion
- Global left ventricle contractility to assess systolic function
- Right ventricle size to assess for right heart strain and pulmonary embolism
- Measurement of inferior vena cava
- Calculation of ejection fraction
- Regional wall motion abnormalities
- Diastolic dysfunction
- Left ventricular hypertrophy diagnosis
- Valvular abnormalities: Mitral/aortic regurgitation & stenosis
- And more...



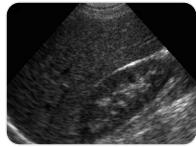
Genitourinary

- Ureteral stone or obstructive process
- Urinary retention & post-void residual
- Stone infection
- Doppler waveform imaging
- Testicular torsion
- Ovarian torsion
- Prostate volume
- And more...



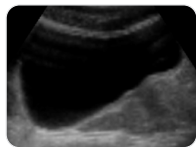
Pulmonary

- Pulmonary ultrasound anatomy
- Pulmonary ultrasound artifacts
- CHF: Presence of bilateral B-lines in lung zones
- Pneumonia
- Pneumothorax
- Pleural effusion and hemothorax
- And more...



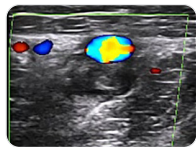
Abdominal

- Symptomatic cholelithiasis
- Acute cholecystitis
- Common bile obstruction
- Appendicitis
- Hepato-splenomegaly
- Small bowel obstruction
- And more...



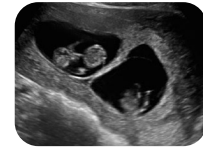
Protocols

- FAST/e-FAST: Focused assessment with sonography for trauma
- RUSH: Rapid ultrasound for shock and hypotension
- BLUE: bedside lung ultrasound in emergency
- CLUE: Cardiac limited ultrasound exam
- FEEDS criteria (See OB-GYN section)
- And more...



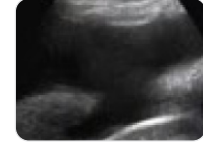DVT

- Doppler waveform imaging/ color
- Vein, artery, nerve, and lymph node
- Low-risk patient
- High-risk patient
- Differentiate DVT from cellulitis of lower extremity, superficial thrombophlebitis and Baker cyst
- Internal jugular, subclavian, axillary, brachial, basilic, and cephalic veins
- And more...



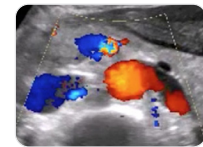
OB/GYN

- Transabdominal & transvaginal
- Presence of IUP & Viability of IUP
- Fetal heart rate - M-mode
- Free fluids in the pelvis
- Placenta position
- Fetal presentation: vertex, breech
- Gestational age assessment
- Evaluation of cervical insufficiency
- Maternal anatomy
- Fetal anatomy & gender of fetus
- Intrauterine device (IUD) position
- Dysfunctional uterine bleeding
- Adnexal mass: hemorrhagic cysts
- And more...



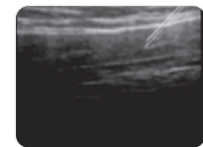
Trauma

- Free fluid in the abdominal cavity
- Free fluid around the heart
- Pneumothorax
- Hemothorax
- And more...



Aorta

- Abdominal aortic aneurysm screening
- Vertebral shadowing, aorta & IVC
- Xiphoid to umbilicus to assess for fusiform vs. saccular aneurysm
- Doppler waveform imaging/color
- Proximal aortic root aneurysm
- Abdominal aortic dissection
- And more...



Procedures

- Thoracentesis
- Paracentesis
- Peripheral IV placement
- Central line placement
- Shoulder Aspiration & injection
- Ankle aspiration & injection
- And more...

\*[https://www.aafp.org/dam/AAFP/documents/medical\\_education\\_residency/program\\_directors/Reprint290D\\_POCUS.pdf](https://www.aafp.org/dam/AAFP/documents/medical_education_residency/program_directors/Reprint290D_POCUS.pdf)